Idiopathic pulmonary fibrosis

Talmadge E King Jr, Annie Pardo, Moisés Selman

Idiopathic pulmonary fibrosis is a devastating, age-related lung disease of unknown cause that has few treatment options. This disease was once thought to be a chronic inflammatory process, but current evidence indicates that the fibrotic response is driven by abnormally activated alveolar epithelial cells (AECs). These cells produce mediators that induce the formation of fibroblast and myofibroblast foci through the proliferation of resident mesenchymal cells, attraction of circulating fibrocytes, and stimulation of the epithelial to mesenchymal transition. The fibroblast and myofibroblast foci secrete excessive amounts of extracellular matrix, mainly collagens, resulting in scarring and destruction of the lung architecture. The mechanisms that link idiopathic pulmonary fibrosis with ageing and aberrant epithelial activation are unknown; evidence suggests that the abnormal recapitulation of developmental pathways and epigenetic changes have a role. In this Seminar, we review recent data on the clinical course, therapeutic options, and underlying mechanisms thought to be involved in the pathogenesis of idiopathic pulmonary fibrosis.

Lancet 2011; 378: 1949–61

Published Online June 28, 2011 DOI:10.1016/S0140-6736(11)60052-4

Department of Medicine, University of California, San Francisco, CA, USA (Prof T E King Jr MD); **Faculty of Sciences, Universidad Nacional Autónoma de México, Ciudad Universitaria, Mexico** (Prof A Pardo PhD); **and Instituto Nacional de Enfermedades Respiratorias, Tlalpan, Mexico** (M Selman MD)

Correspondence to: Prof Talmadge E King Jr, Department of Medicine, University of California, San Francisco, 505 Parnassus Avenue, Box 0120, San Francisco, CA 94143-0120, USA **tking@medicine.ucsf.edu**

Introduction

Idiopathic pulmonary fibrosis (IPF), the most common form of the idiopathic interstitial pneumonias, is a chronic, progressive, irreversible, and usually lethal lung disease of unknown cause. IPF occurs in middle-aged and elderly adults (median age at diagnosis 66 years, range 55–75 years), is limited to the lungs, and is associated with a histopathological or radiological pattern typical of usual interstitial pneumonia.[1–3]

The main histopathological features of usual interstitial pneumonia, best seen at low magnification, is a heterogeneous appearance with areas of subpleural and paraseptal fibrosis and honeycombing (ie, cystic fibrotic airspaces lined by bronchiolar epithelium and often filled by mucin and variable numbers of inflammatory cells) alternating with areas of less affected or normal parenchyma (spatial heterogeneity). Small areas of active fibrosis (fibroblast foci) are present in the background of collagen deposition, and they reflect the temporal heterogeneity of the process and indicate current ongoing disease. Inflammation is usually mild and consists of a patchy lymphoplasmacytic interstitial infiltrate (figure 1). The presence of a usual-interstitial-pneumonia pattern on high-resolution CT is characterised by reticular opacities, often associated with traction bronchiectasis, with little or no ground-glass opacifications (figure 1). Honeycombing, manifested as subpleural, clustered cystic airspaces with well-defined walls (typically 3–10 mm in diameter), is common and is critical for making a definite diagnosis.[1–3]

Patients with IPF usually seek medical attention because they suffer chronic and progressive exertional dyspnoea and cough. Bibasilar inspiratory crackles are heard on chest auscultation and frequently finger clubbing is found. The natural history of IPF has been characterised as a steady or slowly progressive lung disorder, and most patients follow this pattern. However, recent findings indicate that IPF is a heterogeneous disease and new clinical phenotypes with distinct patterns of survival are being described. The pathogenic mechanisms are unclear, but a growing body of evidence indicates that the disease is the result of an abnormal behaviour of the alveolar epithelial cells that provoke the migration, proliferation, and activation of mesenchymal cells, with the formation of fibroblast and myofibroblast foci. Activated myofibroblasts secrete exaggerated amounts of extracellular matrix molecules with the subsequent destruction of the lung architecture.

Epidemiology and risk factors

The annual incidence of IPF is rising and is estimated to be between 4·6 and 16·3 per 100 000 people and the prevalence is 13 to 20 cases per 100 000.[3–6] There is a higher predominance of the disease in men (1·5 to 1·7:1) than in women and the frequency increases with age.[4] The most important environmental risk factors are cigarette smoking and exposure to metal and wood dust.[1,3] Genetic transmission occurs in about 0·5–3·7% of patients with IPF,[5] although this frequency might be higher.[7] Most affected families have an autosomal dominant vertical transmission pattern of inheritance with reduced penetrance. Familial cases of lung fibrosis are often missed. The effect of several comorbid conditions—obesity,[8] diabetes mellitus,[9] gastroesophageal reflux,[10] pulmonary hypertension,[11] obstructive sleep apnoea,[12] coronary artery disease,[13] and emphysema[14]—on the clinical course of IPF remains to be fully defined.

Diagnosis

The diagnosis of IPF often requires a multidisciplinary approach, involving pulmonologists, radiologists, and pathologists experienced in the field of interstitial lung diseases.[15] A pattern indicative of usual interstitial

Search strategy and selection criteria

We searched PubMed from January, 1996, to April, 2011, using the search terms "pulmonary fibrosis", "fibrosing alveolitis", "usual interstitial pneumonia", and "nonspecific interstitial pneumonia". We also searched these terms alongside several subsets of terms as follows: definition and epidemiology; risk factors; natural history and acute exacerbation; staging and prognosis; and pathogenesis, treatment, and biomarkers. We mostly selected publications from the past 5 years although we also included highly regarded older publications. Reviews are cited to provide the reader additional detail and references. The search was limited to reports published in English.

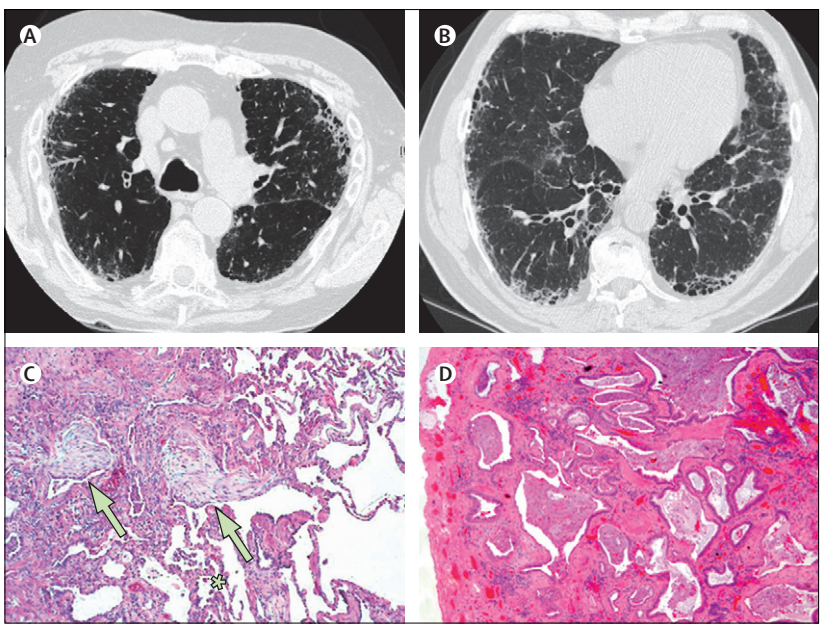

Figure 1: **Pattern typical of usual interstitial pneumonia on high-resolution CT and on histopathology slides**
High-resolution CT shows changes consistent with the usual interstitial pneumonia pattern—ie, the presence of patchy, subpleural reticular opacities and honeycombing with basal predominance (A, B). The key histological feature of the usual interstitial pneumonia pattern is a notable temporal heterogeneous appearance (C) with alternating zones of abnormal and normal lung tissue visible side by side, without transition zones. There is architectural destruction, dense fibrosis, and areas of relatively normal lung tissue (asterisk). Interstitial inflammation is mild and associated with hyperplasia of type II pneumocytes. The temporal heterogeneity in the fibrotic zones is indicated by the presence of dense acellular collagen and juxtaposed with fibroblastic foci of loose organising connective tissue (arrows). Area of honeycomb change composed of cystic fibrotic airspaces (D) are lined with bronchiolar epithelium and filled with mucin.

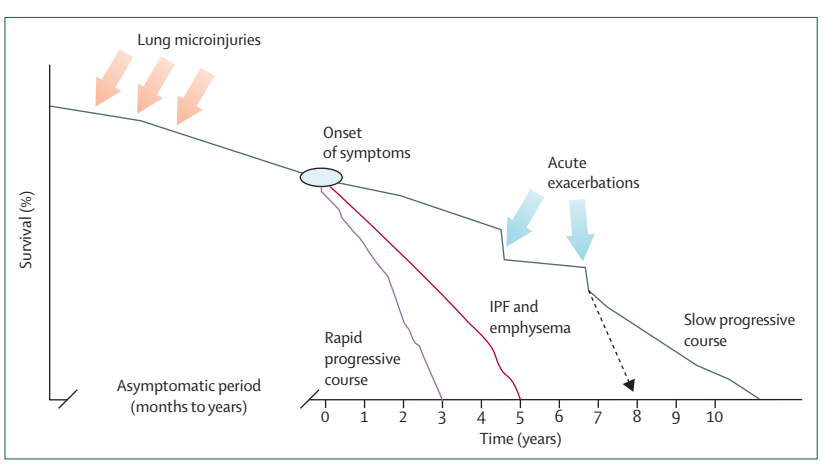

Figure 2: **Clinical phenotypes of IPF**
The heterogeneous natural history pattern in patients with IPF. The disease has a long (months to years) asymptomatic period. Patients consult when the severity of the lung lesions reaches a threshold that is enough to provoke symptoms. Most patients follow a relatively slow clinical and functional decline (slowly progressive) after diagnosis. About 10% of these patients present with episodes of acute clinical deterioration (acute exacerbations) that precede and possibly initiate the terminal phase of their disease. A few patients have a short duration of illness with a rapidly progressive clinical course. Heavy smokers might develop pulmonary fibrosis combined with emphysema, with shorter survival compared with patients with IPF alone. IPF=idiopathic pulmonary fibrosis.

pneumonia on high-resolution CT (figure 1) or on lung tissue obtained by surgical lung biopsy (figure 1) is crucial for the final diagnosis.[1–3] The major differential diagnostic consideration is fibrotic nonspecific interstitial pneumonia, and other forms of idiopathic interstitial pneumonias and interstitial lung diseases associated with occupational or environmental exposure, systemic disease, or drugs need to be excluded.[1,2] Serological evaluation for connective tissue diseases is recommended, even in the absence of signs or symptoms of such diseases.[16] Reliable biomarkers from blood samples or bronchoalveolar lavage fluid, which might be useful for differential diagnosis or prediction of outcome, are poorly defined.[17,18]

Clinical phenotypes and prognosis

IPF has a heterogeneous clinical course, and patients have a median survival of 2·5–3·5 years after diagnosis. Clinical phenotypes with distinct patterns of comorbidities and survival are being defined (figure 2). Worse prognosis is associated with old age (>70 years of age), smoking history, low body-mass index, severe physiological impairment, large radiological extent of disease, and pulmonary hypertension.[17]

Stable or slowly progressive course

Many patients with IPF have a relatively slow clinical course and usually consult doctors for months to years after the beginning of symptoms (cough and progressive dyspnoea). At presentation, patients have decreased lung volumes and capacities, with hypoxaemia at rest that worsens with exercise. In the placebo groups of large clinical trials, the mean annual rate of decline in forced vital capacity ranges from 0·13 L to 0·21 L.[17]

Accelerated variant

A subgroup of patients, mainly male cigarette smokers, has a rapidly progressive course with shortened survival, known as accelerated IPF. In these cases, the transcriptional signature indicates the upregulation of several functional pathways, which mostly operate in alveolar epithelial and mesenchymal domains.[19] Accelerated IPF differs in clinical course and transcriptional profile from the typical slowly progressive form, despite having similar lung function, chest imaging, and histological findings at the time of diagnosis. Boon and co-workers[20] reported that the upregulated genes in the group whose disease progressed rapidly included members of the MAPK–EGR1–HSP70 (mitogen-activated protein kinase–early-growth response gene protein–heat shock protein 70) pathway, which regulate cigarette smoke-induced inflammation.

Acute exacerbation

Acute exacerbation of IPF is defined by rapid deterioration of the disease in the absence of infection, heart failure, pulmonary embolism, or other identifiable cause.[21,22] Diagnosis is made by a combination of clinical (worsening of dyspnoea within days to few weeks), physiological (severe decrease of PaO_2 in arterial blood), and radiographical findings (bilateral ground-glass opacities and consolidation superimposed on a pattern typical of

usual interstitial pneumonia on high-resolution CT).[23] Acute exacerbation of IPF is estimated to affect 5–20% of cases.[21,24,25] Patients with this acute exacerbation have poor outcomes, with mortality exceeding 60% during admission to hospital, and among those who survive there is a >90% mortality within 6 months after discharge.[21,25] Torque teno virus was detected in 27% of IPF cases during periods of acute exacerbation.[26] Morphologically, diffuse alveolar damage superimposed on typical features of usual interstitial pneumonia can be seen. The pathogenic mechanisms are unknown, but widespread epithelial apoptosis has been reported.[27] Circulating fibrocytes might be involved because the numbers of these cells increase during an acute exacerbation and return to pre-exacerbation concentrations in patients who recover.[28]

Pulmonary fibrosis and other lung disorders

Diagnosis of combined pulmonary fibrosis and emphysema is based on high-resolution CT findings that show emphysematous lesions in the upper lobes and usual interstitial pneumonia-like lesions in the lower lobes (figure 3).[14,29,30] Whether combined pulmonary fibrosis and emphysema is a distinct clinical condition, a different clinical phenotype in smokers developing IPF, or the presence of two different diseases running in parallel is unclear. Patients with combined pulmonary fibrosis and emphysema are commonly men who heavily smoke cigarettes and who have severe dyspnoea on exertion and have relatively conserved lung volumes associated with disproportionate impairment of gas exchange. These patients develop early and severe pulmonary arterial hypertension and they have a worse survival compared with patients with IPF who do not have emphysema.[14,29]

Combined pulmonary fibrosis and pulmonary hypertension has a negative effect on prognosis in patients with IPF. This combined disorder is associated with low diffusing capacity for carbon monoxide, shorter walk distances, desaturation during exercise, and an increased risk of death.[11,31–33]

Bronchogenic carcinoma commonly occurs in patients with IPF (9·8–38%).[34] The mechanisms underlying the apparent association of IPF and cancer are unclear. There is an association with cigarette smoking; however, most lung cancers in patients with combined pulmonary fibrosis and cancer are in peripheral areas involving fibrosis and severe epithelial abnormalities, implicating the fibrotic process itself in the pathogenesis of lung cancer.[34,35] Chronic DNA damage leading to p53 gene mutation[36,37] and allelic loss of the gene that encodes the fragile histidine triad (*FHIT*) might be involved in carcinogenesis associated with IPF.[38] Additionally, the Torque teno virus has been implicated.[39] Intriguingly, some cases of lung cancer occurred in patients with familial IPF associated with rare mutations in the gene that encodes surfactant protein A2 (*SFTPA2*).[40]

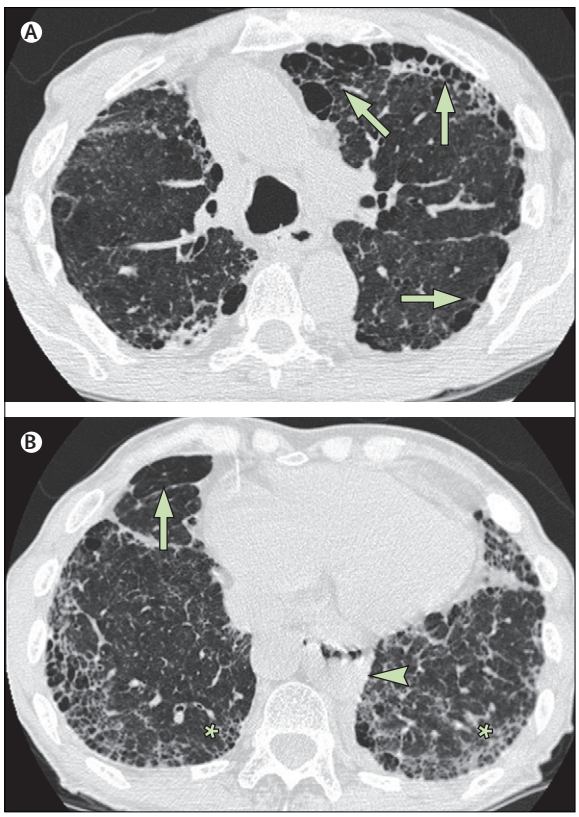

Figure 3: **Combined pulmonary fibrosis and emphysema**
High-resolution CT shows emphysematous lesions (arrows) in the upper lobes (A) and emphysema (arrow) and usual interstitial pneumonia-like lesions (stars) in the lower lobes (B). A hiatal hernia is also present (arrowhead).

Pathogenesis

From an inflammatory-driven to an epithelial-driven disease

Inflammation has a pivotal role in most interstitial lung diseases and, if chronic, evolves to fibrosis. However, with the redefinition of IPF as a distinct condition characterised by the pattern typical of usual interstitial pneumonia,[1,2] the progressive fibrotic reaction in IPF was associated with an epithelial-dependent fibroblast-activated process (figure 4) and a poor response to anti-inflammatory therapy.[41] However, deregulated adaptive immune mechanisms and subsequent inflammation could have a role in the onset or progression of the disease in a subgroup of patients with IPF.[16,42] Therefore, at least two different cellular routes—the inflammatory pathway and the epithelial pathway—could lead to lung fibrosis.[43,44]

Epithelial injury and activation: genetic and environmental interactions

Several environmental factors might contribute to epithelial injury and apoptosis, including cigarette smoking and chronic silent microaspiration.[3,10] Additionally, chronic viral infection, mainly herpes virus infection, might contribute to the pathogenesis of IPF.[45–48]

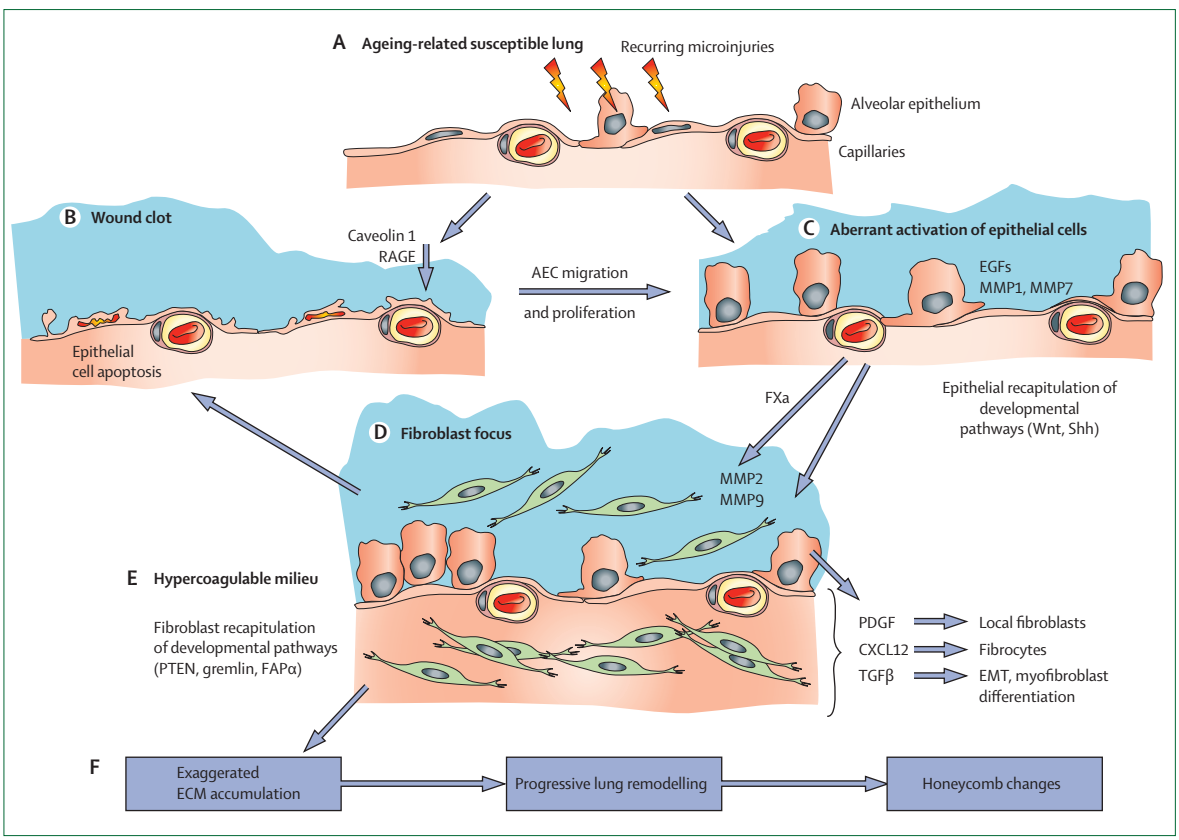

Figure 4: **Proposed mechanisms involved in the pathogenesis of idiopathic pulmonary fibrosis**
(A) In the initial step, ageing-related susceptible lung (eg, by genetic or epigenetic changes, abnormal telomere shortening, poor regenerative capacity) is targeted by repetitive microinjuries (ie, viruses, cigarette smoke, microaspiration) that provokes type I and type II epithelial cell death. (B) After microinjuries and epithelial cell apoptosis, increased vascular permeability to proteins (eg, fibrinogen, fibronectin) causes the formation of a provisional matrix (wound clot). (C) This pathological process is followed by bronchiolar and AEC migration and proliferation in a frustrated effort of lung repair (ie, aberrant activation of epithelial cells). Several epidermal growth factors (eg, hepatocyte growth factor and hepatoma-derived growth factor) participate in the proliferative response. Furthermore, MMP1 and MMP7 contribute to the epithelial cell migration. In this microenvironment, epithelial cells are abnormally activated (epithelial recapitulation of developmental pathways) and produce diverse growth factors and chemokines, inducing the migration of resident fibroblasts and bone marrow-derived progenitors of fibroblasts (fibrocytes) to the sites where the microinjuries are occurring. Additionally, they secrete and activate the latent TGFβ1, which promotes EMT and the differentiation of fibroblasts to myofibroblasts. (D) Together, and in unknown proportions, these cells (fibrocytes, local mesenchymal cells, and myofibroblasts derived from EMT) participate in the formation of the fibroblast and myofibroblast focus. Matrix metalloproteinases, such as MMP2 and MMP9, contribute to the activation of TGFβ and to the disruption of the basement membranes. (E) In the alveolar epithelium, the TF–FVIIa–FX complex is assembled, with the subsequent activation of FX to FXa. This procoagulation state provokes a hypercoagulable milieu that avoids the degradation of the provisional matrix and enhances a fibrogenic milieu. Fibroblasts and myofibroblasts are also indicative of recapitulation of developmental pathways. (F) In the foci, myofibroblasts secrete excessive amounts of extracellular matrix proteins, mainly fibrillar collagens, and can also provoke additional epithelial apoptosis through hydrogen peroxide and other molecules. In this progressive abnormal lung remodelling, several neighbouring scars, together with the disproportionate secretion of some enzymes (eg, MMP1) can provoke the formation of the honeycomb cysts through mechanical forces. AEC=alveolar epithelial cells. CXCL12=CXC chemokine ligand 12. ECM=extracellular matrix. EGF=epithelial growth factor. EMT=epithelial-mesenchymal transition. FVIIa=Factor VIIa. FX=Factor X. FXa=Factor X activated. FAPα=fibroblast activation protein α. MMP=matrix metalloproteinase. PDGF=platelet-derived growth factor. PTEN=phosphatase and tensin homologue. RAGE=receptor for advanced glycation end products. Shh=sonic hedgehog. TF=tissue factor. TGFβ=transforming growth factor β.

There are no genetic factors consistently associated with sporadic IPF.[49] Alterations in unfolded protein response occur in some familial cases of pulmonary fibrosis that have mutations in surfactant protein C, a hydrophobic protein expressed exclusively by AEC type II (AEC II).[50] Missense or short-deletion mutations of this protein result in the production of misfolded protein, which, by accumulation or complex formation, can cause epithelial cell injury. A common polymorphism in the promoter region of mucin 5B gene (*MUC5B*) is associated with familial interstitial pneumonia and sporadic IPF. MUC5B is a gel-forming mucin expressed by bronchial epithelial cells. Dysregulated *MUC5B* expression is associated with chronic airway disease and these findings suggest a role in the pathogenesis of pulmonary fibrosis.[51,52]

Data from a genome-wide scan in six families with familial IPF identified a shared haplotype on chromosome 4q31, which was significantly more frequent in patients than in population-based controls.[53] This haplotype harboured *ELMOD2*, a gene expressed in lung, however, it was expressed significantly less in IPF lung when compared with that of the healthy lung. *ELMOD2* is essential for cellular processes and might have an antiviral effect in AECs.[54] Mutations of

telomerase have been implicated in familial pulmonary fibrosis (see below).

Despite epithelial injury and apoptosis, an increased number of hyperplastic and hypertrophic type II pneumocytes is a notable feature of lungs affected by IPF. Additionally, large and elongated or attenuated epithelial cells are observed. Bronchiolar-type epithelium and squamous metaplasia lining the honeycomb lesions are also reported. Epithelial cells are highly active, leading to a dysregulated repair process that seems to be perpetually turned on even in the absence of the primary stimulus.[41]

Emerging evidence indicates that deregulation of some embryological pathways might explain the abnormal behaviour of AECs and perhaps of fibroblasts in IPF.[55] Wnt ligands comprise a large family of secreted glycoproteins essential to morphogenetic processes. Results from several studies indicate that alveolar epithelium and fibroblasts overexpress members of the Wnt/wingless pathway in lungs affected by IPF.[56–59] Additionally, there is extensive nuclear accumulation of β catenin in AECs and fibroblasts, suggesting that the Wnt–β-catenin pathway is switched on in both cell types.[60]

Phosphatase and tensin homologue (PTEN) is crucial for development. In adults, PTEN participates in the regulation of physiological processes such as cell polarity, proliferation, and apoptosis.[61] In patients with IPF, PTEN expression is downregulated in myofibroblasts within fibroblastic foci, which might account for their assumed resistance to apoptosis.[62] β1 integrin–collagen interaction in normal fibroblasts activates PTEN, which is also a negative growth regulator, whereas this negative feedback mechanism is defective in IPF fibroblasts.[63]

Sonic hedgehog (Shh) is an essential morphogen for patterning during embryogenesis. This developmental ligand enables cells to evade apoptosis and cell cycle arrest, conferring a proliferative advantage. In lungs affected by IPF, a strong expression of Shh was reported, mainly in epithelial cells lining honeycomb cysts.[64,65]

Bone morphogenetic proteins belong to the transforming growth factor β (TGFβ) superfamily and have an essential role in embryonic and postnatal development.[66] In adults, reactivating the expression of bone morphogenetic protein antagonists can contribute to the progression of some chronic degenerative diseases. Increased expression of gremlin, a strong bone morphogenetic protein antagonist, has been reported in fibroblasts in lungs affected by IPF.[67] Increased concentrations of gremlin could attenuate phosphorylation mediated by bone morphogenetic protein signalling in lungs, leading to increased TGFβ1-induced epithelial to mesenchymal transition (EMT) and decreased myofibroblast apoptosis.

In summary, some developmental programmes are probably activated during normal tissue repair. However, this process must be tissue specific and temporally modulated. Conversely, sustained deregulation might contribute to the pathogenesis of IPF. The upregulation of Wnt, Shh, and gremlin 1 and the downregulation of PTEN are important pieces of evidence indicating that IPF could occur as part of recapitulation of developmental pathways, thus contributing to a maladaptive repair process.

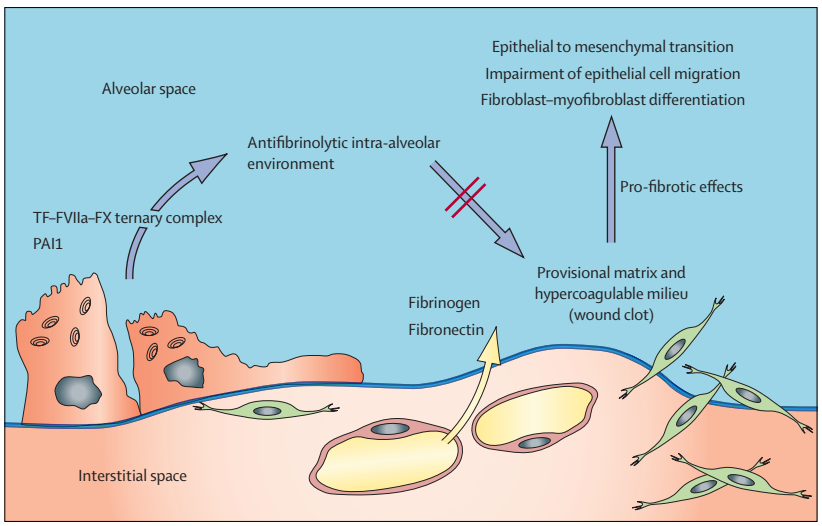

Figure 5: **Wound clot and the profibrotic role of local activation of signalling via coagulation factors**
After lung injury there is capillary leakage of proteins, including fibrinogen and fibronectin, into the interstitial and alveolar spaces with the formation of a provisional matrix (wound clot). In the abnormally activated epithelial cells, TF, FVII, and FX form a ternary complex. Activated FX converts prothrombin into thrombin, which in turn cleaves fibrinogen into fibrin. Additionally, epithelial cells secrete PAI 1, which contributes to the creation of an antifibrinolytic, hypercoagulable microenvironment, thereby avoiding the degradation of the provisional matrix. The persistence of the wound clot and active proteases from the coagulation cascade trigger several mechanisms involved in the fibrotic tissue remodelling, including epithelial to mesenchymal transition. PAI=plasminogen activator inhibitor 1. TF=tissue factor. FVIIa=Factor VIIa. FX=Factor X.

Profibrotic effects of aberrantly activated AECs in the lung microenvironment

An important pathological process in IPF is the activation of the coagulation cascade, which has several profibrotic effects (figure 5).[68,69] In IPF, the tissue factor–Factor VIIa–Factor X complex assembles on the alveolar epithelium, allowing activation of Factor X, which in turn stimulates fibroblasts within the underlying fibrotic regions. Provisional matrix, formed by fibrin and fibronectin, could stimulate EMT even in the absence of TGFβ1.[70] Additionally, thrombin and activated Factor X induce the differentiation of lung fibroblasts to myofibroblasts via the proteinase-activated receptor 1.[71,72] These findings provide compelling evidence that procoagulant signalling is activated in IPF and that deficient function of alveolar fibrinolysis, mainly caused by the epithelial cells, has an important role in driving the fibrotic lung response.

In injured tissues, fibroblasts are activated and differentiate into myofibroblasts, which are specialised contractile cells with higher profibrotic potential than fibroblasts. In the fibroblastic foci, these cells cause the exaggerated extracellular matrix deposit—the hallmark of the scarring process that leads to the destruction of the lung architecture. The origin of fibroblasts and myofibroblasts and the reasons why they organise in morphologically distinct foci in IPF is unclear (figure 6).

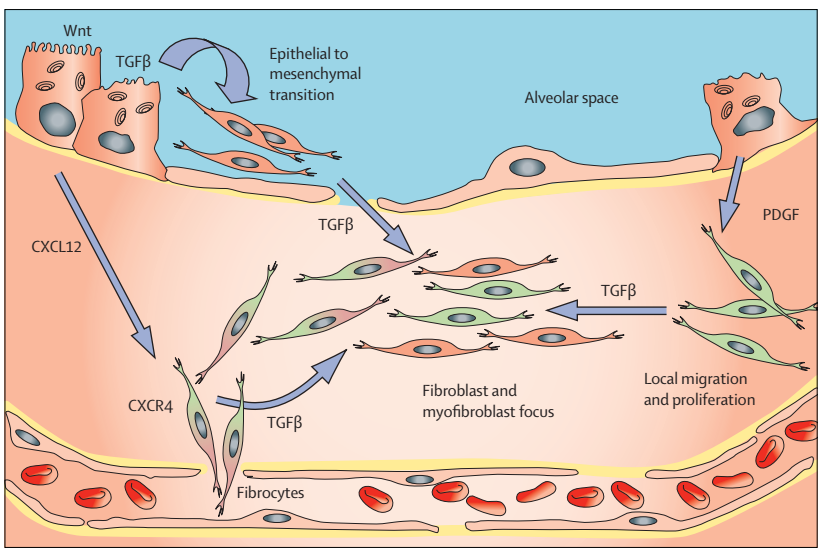

Figure 6: **Overview of the sources of recruitment of fibroblasts during the development of idiopathic pulmonary fibrosis**

Activated alveolar epithelial cells secrete CXCL12—the sole ligand for the chemokine receptor CXCR4, which is the main receptor of human fibrocytes. Fibrocytes are, in turn, chemoattracted from the peripheral blood to the injured areas. Additionally, epithelial cells secrete strong chemotactic and mitogen growth factors such as PDGF, inducing the migration and proliferation of resident mesenchymal cells. Finally, under different stimuli, including TGFβ1 and wound clotting, epithelial cells might evolve to fibroblasts through an epithelial to mesenchymal transition process. In the local microenvironment, fibroblasts form small clusters (fibroblast foci) and differentiate to myofibroblasts that have a more aggressive profibrotic phenotype. CXCL=chemokine ligand. CXCR=chemokine receptor. PDGF=platelet-derived growth factor. TGFβ=transforming growth factor β.

Strong evidence indicates that AECs are the primary source of mediators that function as chemotactic factors or mitogens for mesenchymal cells, including platelet-derived growth factor, TGFβ, tumour necrosis factor α, and endothelin 1.[68] These factors probably contribute mostly to the migration, proliferation, and differentiation of resident mesenchymal cells.

There is an influx of circulating fibrocytes into lungs affected by IPF.[73] Fibrocytes are a unique subpopulation of leucocytes characterised by the expression of haemopoietic (CD45, CD34) and mesenchymal (collagen I, fibronectin) cell markers.[74] Most human circulating fibrocytes express the chemokine receptor CXCR4, suggesting that the CXCR4–CXCL12 axis is crucial for trafficking into IPF lungs. AECs from these patients strongly express CXCL12, which probably forms the chemotactic gradient needed for trafficking of CXCR4-positive fibrocytes.[73]

The epithelium might directly contribute to the expansion of the population of fibroblasts and myofibroblasts through the EMT. In this process, epithelial cells acquire mesenchymal properties through which they increase their capability to move and to synthesise interstitial matrix.[55,75] Evidence that supports the EMT as a source of IPF myofibroblasts include co-localisation of epithelial (prosurfactant proteins) and mesenchymal (alpha-smooth muscle actin [alpha-SMA], N-cadherin) markers in AECs from IPF lungs,[70,76] the expression of typical epithelial proteins (ie, keratin 18) in IPF fibroblasts,[77] and alveolar type II cells from fibrotic human lungs have increased expression of genes encoding mesenchymal proteins and potential regulators of EMT.[78]

Additionally, there are strong drivers of EMT in lungs of patients with IPF. SNAI transcription factors, key regulators of TGFβ1-induced EMT in the lung, are increased in hyperplastic AECs.[79,80] Depletion of SNAI1 and SNAI2 with small interfering RNA inhibited TGFβ1-induced EMT. Twist, another driver of EMT, was reported in hyperplastic AECs from the lungs of patients with IPF. Interestingly, IPF tissue with high Twist protein levels was also positive for the herpesvirus, EBV. In IPF, EBV infection might be a source of injury precipitating EMT through the expression of Twist.[81]

Thus, local mesenchymal cells, circulating fibrocytes, and EMT participate in the expansion of fibroblasts and myofibroblasts in IPF. However, the relative quantitative contribution of each process in the onset, progression, or perpetuation of IPF is unknown. In experimental lung fibrosis in mice, EMT accounted for about 33% of fibroblasts, and bone marrow progenitor recruitment accounted for about 20% of fibroblasts.[82] We can assume that, at least in this model, the remaining 50% of fibroblasts originate from resident mesenchymal cells (or another undisclosed source [eg, pericytes, and endothelial or mesothelial to mesenchymal transition]).

Differentiation of fibroblasts to myofibroblasts

Three main factors drive the differentiation of fibroblasts to myofibroblasts and guarantee maintenance of the contractile phenotype: high mechanical stress (that induces the differentiation to proto-myofibroblasts), local increase of active TGFβ1 (mainly produced by AECs in IPF), and the presence of specialised matrix proteins, such as the extra domain A (ED-A) splice variant of fibronectin.[83] Myofibroblasts cause the exaggerated accumulation of extracellular matrix (fibrosis) and contribute to basement membrane disruption and epithelial cell death (figure 7).[84,85]

Elimination of myofibroblasts by apoptosis is essential during normal wound healing; this process does not seem to occur in the fibroblastic foci of IPF. Microenvironmental signals such as TGFβ1 and endothelin 1 (mostly synthesised by AECs in IPF) might promote fibroblast resistance to apoptosis through signalling pathways involving PI3K/AKT.[86] However, there is no convincing evidence that reduced susceptibility to apoptosis can cause the persistence of myofibroblasts in vivo.[87] Moreover, the reasons why fibroblasts and myofibroblasts apparently survive while epithelial cells die within the same microenvironment (the apoptosis paradox) is unclear.[87] A potential explanation might be related to prostaglandin E2 deficiency (usually observed in IPF), which increases AECs sensitivity to apoptosis but decreases fibroblast sensitivity to apoptosis.[88]

The absent type I pneumocytes

AECs type I cover more than 90% of the alveolar surface area of the peripheral lung and, interfacing with

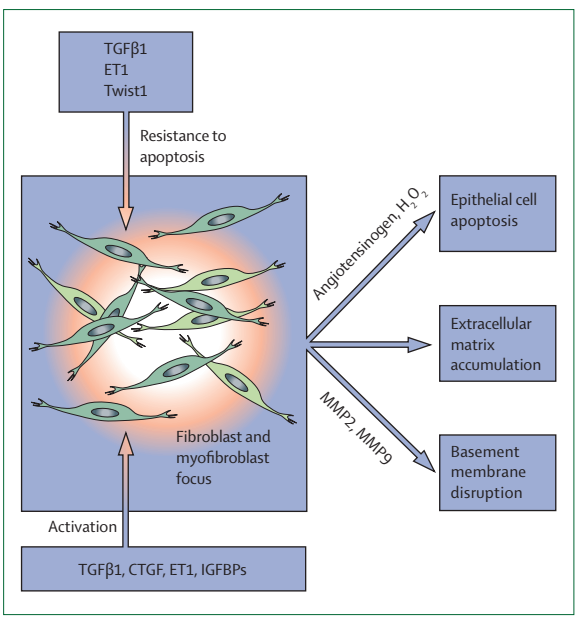

Figure 7: **Formation and deleterious effects of the fibroblast focus**
Fibroblasts and myofibroblasts accumulate in small collections that seem to persist in the focus because of resistance to apoptosis. Activated myofibroblasts secrete angiotensinogen and H_2O_2 that induce alveolar epithelial cell death. They also produce matrix metalloproteinases such as MMP2 and MMP9, which are implicated in the disruption of the epithelial basement membrane. TGFβ1=transforming growth factor β1. ET1=endothelin 1. CTGF=connective tissue growth factor. IGFBPs=insulin growth factor-binding protein. H_2O_2=hydrogen peroxide. MMP=matrix metalloproteinase.

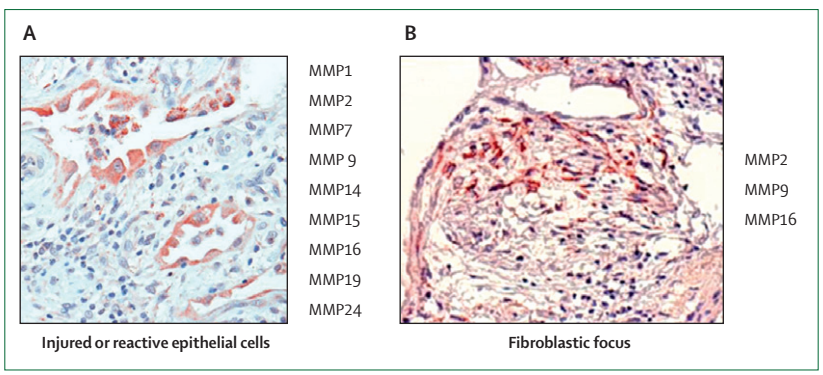

Figure 8: **Matrix metalloproteinases in idiopathic pulmonary fibrosis**
MMPs have an important role in the pathogenesis of idiopathic pulmonary fibrosis. Most are localised in aberrant alveolar epithelial cells, with very few in the fibroblastic foci. Strong cytoplasmic staining of MMP1 in epithelial cells (A) and MMP2 in fibroblasts (B) is shown. MMP=matrix metalloproteinase.

pulmonary capillaries, provide a surface readily permeable to gases. Patients with IPF have an important loss of type I pneumocytes, although the putative effect of this pathological process on the fibrotic response is unclear. Furthermore, transdifferentiation of type II pneumocytes into type I pneumocytes, indispensable to re-establish a functional alveolar epithelium, is profoundly altered in IPF because of the severe abnormalities of the extracellular matrix and interrupted epithelial basement membrane.

The loss of AEC type I might provoke the reduction of some important antifibrotic molecules (eg, caveolin 1).[89] However, whether decreased concentrations of caveolin 1, specifically attributable to the loss of type I pneumocytes, is involved in IPF pathogenesis is not known. Furthermore, the receptor for advanced glycation end products (RAGE) is also decreased in IPF. RAGE is a member of the immunoglobulin superfamily of cell surface receptors that is highly expressed by normal AEC type I.[90,91] The loss of this receptor might result in decreased binding of AEC type I to the basement membrane, thus preventing the proper re-epithelialisation of alveoli during fibrogenesis.[92,93]

Matrix metalloproteinases and the abnormal lung remodelling

Gene-expression signatures have indicated that matrix metalloproteinase 7 (MMP7), MMP1, and MMP2 are among the most highly expressed genes in IPF.[56,94] Additionally, other MMPs have been reported in the bronchoalveolar lavage (eg, MMP3, MMP8, and MMP9) or have been localised by immunohistochemistry in lungs affected by IPF (eg, membrane-type MMPs).[95–97] Most of these MMPs are localised in the AECs; few are in the fibroblastic foci (figure 8).

MMP1 is mainly localised in the epithelium and is almost absent in the interstitial compartment, where collagen accumulates. MMP7 and osteopontin interact to affect the IPF phenotype (ie, MMP7 is induced by osteopontin, and osteopontin is also cleaved and activated by MMP7).[98] Both MMP1 and MMP7 facilitate epithelial cell migration, reducing the affinity of the α2β1 integrin.[99] The increased expression of MMP1 might be partly associated with the presence of two gene polymorphisms that affect its transcriptional responsiveness.[100] Increased concentrations of MMP2 is consistently reported in alveolar and bronchiolar epithelial cells and in fibroblastic foci. The major activators of proMMP2 are members of the membrane-type MMP family that are also strongly expressed in lungs affected by IPF.[96] Therefore, the increased amount of active MMP2 might be attributed to the action of these enzymes. MMP9 is also elevated in IPF, and an increase in the active form of MMP9 in the bronchoalveolar lavage is associated with an accelerated clinical phenotype.[19] An improved understanding of the complexity of MMP proteolysis and their in-vivo substrate repertoires will help to define the fibrosis-specific effects of MMPs in IPF.

Angiogenesis and vascular remodelling

Neovascularisation is a fundamental process in tissue repair after injury and is affected by the balance between various factors—mainly chemokines that promote or inhibit angiogenesis.[101] There is increased angiogenesis in experimental lung fibrosis; however, the role of this angiogenesis in IPF is unclear. An aberrant vascular remodelling occurs in lungs affected by IPF but fibrotic areas have fewer blood vessels, whereas adjacent non-fibrotic tissue is highly vascularised.[102] There are almost no

capillaries within the fibroblastic foci, indicating that the fibrotic process in IPF does not need neovascularisation.[103] Thus, under certain pathological settings, increased angiogenesis seems to have a fibrogenic role, whereas, in other settings, decreased angiogenesis enhances fibrosis.

Processes that link ageing with IPF

The mechanisms that link ageing with IPF remain elusive. High-resolution CT findings usually associated with IPF are frequently seen in asymptomatic elderly individuals (75 years or older) and are absent in younger patients.[104] One possible mechanism is related to an accelerated shortening of telomeres.[105] Telomeres shorten successively with each cell division—when they achieve a critical length, they activate a p53-dependent checkpoint that leads to apoptosis or replicative senescence.[105] Short telomeres are expected to compromise the replicative potential of progenitor cells that remain in tissues after injury.

The results from two studies identified loss-of-function mutations of telomerase in 8–15% of patients with familial IPF.[106,107] Subsequently, it was found that patients with sporadic IPF had short leucocyte telomeres; short telomeres were also detected in the alveolar epithelium.[108] Thus, such individuals might be at increased risk for developing IPF. Some patients with other forms of IPF also had shortened telomeres, raising the possibility of shared mechanisms.[108]

However, shortening of telomeres is also observed in chronic obstructive pulmonary disease, another age-related but completely different lung disease.[109] Moreover, telomerase-deficient mice that have sequential shortening of telomeres develop spontaneously emphysematous-like lesions. AECs from these mice show activation of the stress response pathway and spontaneous apoptosis,[110] indicating that, in this model, telomere shortening causes epithelial cell damage, but the consequence is an emphysema-like disorder not fibrosis. Additionally, evidence of epithelial alveolar apoptosis has been also reported in human emphysema.[111–114] Nevertheless, the whole population shift in the distribution in the telomere length suggests that telomere shortening might be a pathogenic co-factor for IPF.

Ageing is also associated with increased oxidative stress as a result of an imbalance of pro-oxidants (reactive oxygen and nitrogen species) and antioxidants (eg, superoxide dismutases, glutathione).[115] The consequences include direct damage to DNA, oxidation of polyunsaturated fatty acids in cell membranes, and inactivation of enzymes. Results from several studies have indicated a severe lung redox imbalance in IPF, probably caused by an increase in oxidants associated with extracellular glutathione deficiency.[116] Excessive oxidative stress has various deleterious effects that might contribute to the pathogenesis of IPF, including activation of redox-sensitive signalling pathways, changes in cytokine or chemokine expression, modification of protease or antiprotease balance, induction of apoptosis, and activation of fibroblasts.[117]

Epigenetic processes involve transmissible alterations in gene expression caused by mechanisms other than changes in DNA sequence, and these processes are essential for normal development and maintenance of tissue-specific gene expression patterns. The most common epigenetic mechanisms include DNA methylation, post-translational modifications of histones, and transcriptional effects of non-coding RNA molecules, including microRNAs.

In the elderly (>65 years of age), there is a progressive loss of DNA methylation in repetitive elements dispersed throughout the genome, which seems to be proportional to life expectancy.[118] An aberrant reprogramming of the epigenome is involved in cancer initiation and progression.[119]

Epigenetic changes contribute to the aggressive behaviour of IPF fibroblasts. Thy1, a receptor that inhibits the differentiation of fibroblasts to myofibroblasts and that decreases fibrogenic activity, is not expressed in fibroblastic foci in vivo.[120] The loss of this receptor occurs by epigenetic silencing through the hypermethylation of cytosine–guanine islands in the gene promoter.

Compared with normal fibroblasts, IPF fibroblasts express less cyclooxygenase 2 and synthesise less prostaglandin E2, a potent downregulator of fibroblast activation.[121] The reduced expression of cyclooxygenase 2 in IPF fibroblasts seems to be caused by epigenetic abnormalities of histone acetylation that prevents activated transcription factors from binding to the cyclooxygenase 2 promoter.[122]

MicroRNAs are post-transcriptional regulators that bind to specific sequences, blocking translation or causing degradation of the target messenger RNA, which results in gene silencing. microRNAs probably control most biological pathways and networks. During ageing, dysregulated expression of microRNAs generally occurs in groups, suggesting that their actions might be functionally coordinated together by common transcriptional regulators.[123] Age-dependent disruption of these vital partnerships might contribute to the development of diseases in elderly individuals. For example, downregulation of some microRNAs (eg, miR1, mirR30) coupled with the upregulation of others (eg, miR20a, miR21) are commonly reported in patients with cardiac hypertrophy and coronary arteriosclerosis.[123] 46 microRNAs were recently reported to be differentially expressed in IPF compared with normal lungs, with a significant decrease of microRNA let-7d.[124] Inhibition of let-7d in vitro induced EMT, whereas inhibition in vivo caused alveolar septal fibrosis. Similarly, lungs affected by IPF have an upregulation of miR21 and a downregulation of miR29, mainly localised to myofibroblasts.[125,126] Increasing miR21 levels promoted the profibrogenic activity of TGFβ1 in fibroblasts, whereas downregulating miR-21 attenuated this activity.[125] By contrast, miR29 levels inversely correlated with the expression of several profibrotic target genes and with the severity of fibrosis.[126]

Therefore, epigenetic deregulation that contributes to the ageing phenotype might increase the risk in developing IPF if a crucial threshold of epimutations is reached.

Treatment approaches

In clinical trials of novel drugs (etanercept,[127] IFNγ,[24,128] bosentan,[129] imatinib mesilate[130]) in patients with IPF who have mild-to-moderate functional impairment, no significant benefit was reported with these interventions. In general, patients with IPF who have moderate-to-severe functional impairment and associated co-morbidities (eg, pulmonary hypertension) have been excluded from trials. Consequently, many patients seen in clinical practice have not been studied. Several clinical trials are ongoing (table).

For several new therapies, there is evidence to suggest clinical benefit in patients with IPF. N-Acetylcysteine, an antioxidant, used in combination with prednisone and azathioprine, reduces the rate of decline in forced vital capacity and diffusing capacity for carbon monoxide after 12 months of treatment.[131] However, the observed changes are of uncertain clinical significance. Pirfenidone, a novel compound that inhibits TGFβ in vitro, decreased the rate of decline in vital capacity and increased the progression-free survival time over 52 weeks.[132] Pooled data from two concurrent phase 3 clinical trials in IPF (CAPACITY 1 and 2) indicated that the mean change in forced vital capacity and 6-min walk distance decline was reduced in the pirfenidone-treated group.[133] In a non-masked IPF trial, patients given prednisolone and anticoagulation (coumadin in outpatients and intravenous dalteparin when admitted to hospital) had improved overall survival at 3 years and reduced mortality associated with acute exacerbation (63% *vs* 35%) compared with patients receiving prednisolone alone.[134] The National Heart, Lung, and Blood Institute (USA) suspended enrolment and treatment in the phase 3, randomised, double-blind, placebo controlled ACE-IPF trial (anticoagulant effectiveness in idiopathic pulmonary fibrosis; NCT00957242). Designed to test the effectiveness of warfarin in patients with IPF, this trial was stopped based upon the recommendation of the independent Data and Safety Monitoring Board overseeing the trial because of the low likelihood that warfarin would be superior to placebo in treating patients with IPF.

Lung transplantation

Lung transplantation is the only therapy that prolongs survival in advanced IPF, although the post-transplantation 5-year survival for patients with IPF is about 44%.[135] Appropriate timing for referral to transplantation is controversial given the variable course of IPF and absence of validated prognostic measures. Patients with IPF are often referred late in the course of their disease and many die before receiving a transplant. Therefore, referring patients for evaluation for transplantation at the time of initial diagnosis would be reasonable.

Stem cell-based therapy

Both embryonic and adult tissue-derived stem cells can participate in the regeneration and repair of diseased adult

	ACE-IPF	PANTHER-IPF	TOMORROW	MUSIC	Thalidomide	CNTO 888
Clinical trials identifier	NCT00957242	NCT00650091	NCT00514683	NCT00903331	NCT00600028	NCT00786201
Full study name (description)	Anticoagulant effectiveness in idiopathic pulmonary fibrosis (phase 3, randomised, double-blind, placebo-controlled trial)	Evaluating the effectiveness of prednisone, azathioprine, and N-acetylcysteine in people with idiopathic pulmonary fibrosis (phase 3, randomised, double-blind trial that evaluates response)	Safety and efficacy of BIBF 1120 in idiopathic pulmonary fibrosis (phase 2, 12-month, double-blind, randomised, placebo-controlled trial)	Macitentan use in an idiopathic pulmonary fibrosis clinical study (phase 2, randomised, double-blind trial)	Treatment of chronic cough in idiopathic pulmonary fibrosis with thalidomide (phase 3, randomised, double-blind, placebo-controlled, crossover trial)	A study to evaluate the safety and effectiveness of CNTO 888 administered intravenously in subjects with idiopathic pulmonary fibrosis (phase 2, multicentre, multinational, randomised, double-blind, placebo-controlled, parallel-group, dose-ranging study)
Study compounds	Warfarin *vs* placebo	Prednisone plus azathioprine plus N-acetylcysteine *vs* N-acetylcysteine *vs* placebo	BIBF 1120 (oral dose escalation: 50 mg once daily, 50 mg twice daily, 100 mg twice daily, and 150 mg twice daily)	10 mg, once daily	Thalidomide *vs* placebo	CNTO 888 (anti CC-chemokine ligand 2) 1 mg/kg or 5 mg/kg or 15 mg/kg *vs* placebo
Patients enrolled (n)	256	390	432	156	20	120
Target population	Advanced disease	Treatment naive (<12 weeks of IPF therapy)	Mild-to-moderate disease	Mild-to-moderate disease (limited HC on HRCT ≤5%)	Mild-to-moderate disease	Mild-to-moderate disease with evidence of progression before enrolment
Primary endpoint	All cause mortality; non-elective admission to hospital; decrease in the absolute FVC ≥10% from baseline	Change in FVC at 60 weeks	Change in FVC at 52 weeks	Change in FVC	Suppression of chronic cough	Efficacy (measured by PFTs) and safety
Sponsor	NIH	NIH	Boehringer Ingelheim	Actelion	Johns Hopkins	Centocor

IPF=idiopathic pulmonary fibrosis. FVC=forced vital capacity. HC=honeycombing. PH=pulmonary hypertension. HRCT=high-resolution CT. PFT=pulmonary function tests. NIH=National Institutes of Health.

***Table*: Ongoing clinical trials in IPF**

organs, including the lungs.[136] The main problem after injury is to re-establish the integrity and functional organisation of the epithelial layer and of the alveolar-capillary units. This process probably occurs during normal repair by the migration and spreading of nearby and newly recruited circulating progenitor cells that proliferate and undergo phenotypic differentiation to cover the denuded surfaces.[137] Mesenchymal stem cells are a promising prospect for tissue regeneration. These cells migrate to the lung, adopt an epithelium-like phenotype, and reduce fibrosis in bleomycin-injured lungs from mice.[138] Additionally, after intratracheal injection of bleomycin, prominin 1–CD133-positive epithelial progenitor cells, co-expressing stem and haematopoietic cell markers engraft in the lungs, differentiate into type II pneumocytes and protect against bleomycin-induced fibrosis.[139] More recently, the therapeutic potential of AEC type II derived from human embryonic stem cells was studied in the mouse model of bleomycin-induced injury. These cells differentiated into type I pneumocytes, and abrogated the inflammatory and fibrotic response.[140] Unfortunately, almost all the experiments have been done in the bleomycin-lung model, which is a modest inflammatory and fibrotic model, spontaneously reversible, and does not represent the progressive and lethal nature of IPF.

Another growing area of investigation is lung bioengineering using decellularised lung tissue repopulated with neonatal lung epithelial cells and microvascular lung endothelial cells.[141] When transplanted, these engineered lungs were effective in exchanging oxygen and carbon dioxide.[141] Although far from human lung bioengineering, this approach is encouraging.

Additional management factors

Patients with acute exacerbations are usually treated with broad-spectrum antibiotics and corticosteroids. Mechanical ventilation is often needed but is usually unsuccessful, with a high hospital mortality rate.[21] For patients who survive and are discharged from hospital, recurrence is common and is usually fatal.

Patients with IPF who have pulmonary arterial hypertension have increased mortality. Consequently, therapy directed against pulmonary arterial hypertension might be beneficial. Sildenafil, an oral drug that preferentially blocks phosphodiesterase 5 in well ventilated areas of the lung, reduces pulmonary vascular resistance and improves gas exchange in patients with severe pulmonary fibrosis.[142] Sildenafil can cause important improvements in dyspnoea and quality of life in patients with advanced disease.[143]

Although the potential pathogenic association between chronic microaspiration and IPF remains unclear, some evidence supports attempts at management of gastroesophageal reflux disease.[10] However, further studies are needed to see if aggressive, chronic treatment of this disease is able to improve or halt further progression of IPF.

Given the link between ageing and IPF, physicians should pay attention to geriatric comorbidities and increase focus on symptom-based management to complement emerging disease-modifying therapies to improve quality of life. Pulmonary rehabilitation, education programmes, and joining support groups can help patients to breathe more efficiently and to perform their activities of daily living with less breathlessness. Supplemental oxygen therapy is commonly needed to treat the hypoxaemia that usually worsens with exercise.

Conclusions

IPF is a devastating lung disease whose incidence and prevalence increases markedly with ageing. The disease course is heterogeneous; however, the median survival is about 3 years after diagnosis. The cause of IPF is unknown, but it appears to be a disorder likely arising from the interplay between environmental and genetic factors. Cigarette smoking is the most consistent environmental risk factor. Gene mutations and polymorphisms have been shown in both sporadic IPF and familial pulmonary fibrosis. Although the pathogenic mechanisms are unknown, a growing body of evidence suggests that the disease process is initiated through alveolar epithelial cell microinjuries and apoptosis, which results in the aberrant activation of neighbouring epithelial cells, the arrival of stem or progenitor cells, or both that in turn produce the factors responsible for the expansion of the fibroblasts and myofibroblasts population in the IPF lungs. These peculiar fibroblastic foci secrete exaggerated amounts of extracellular matrix components that destroy the lung parenchyma. No effective treatment exists. Lung transplant is the only treatment that prolongs the life of patients with IPF. Thus, the fundamental challenge for the future is to find appropriate therapeutic approaches that will reverse or stop the progression of the disease. Combination of drugs that target epithelial cells and fibroblasts, and, crucial signalling pathways could, at least theoretically, open new therapeutic opportunities. Another new strategy includes the use of stem cells (eg, embryonic or induced-pluripotent, or mesenchymal stem cells) to rebuild the fibrotic lungs. Finally, the absence of a fitting animal model (or an in-vitro system) that would allow preclinical testing of potential drugs is a crucial missing link.

Contributors

All authors contributed equally to the design, literature search, figures, and writing of this manuscript.

Conflicts of interest

TK's institution has received fees for consultancy work or for work on an advisory committee from InterMune, Actelion, Gilead, ImmuneWorks, and Genzyme, and has received grants from the NIH for the IPFnet study.

References

1 American Thoracic Society. Idiopathic pulmonary fibrosis: diagnosis and treatment. International consensus statement. American Thoracic Society (ATS), and the European Respiratory Society (ERS). *Am J Respir Crit Care Med* 2000; **161:** 646–64.

2 American Thoracic Society/European Respiratory Society. International multidisciplinary consensus classification of the idiopathic interstitial pneumonias. *Am J Respir Crit Care Med* 2002; **165:** 277–304.

3 Raghu G, Collard HR, Egan J, et al. An official ATS/ERS/JRS/ALAT statement: idiopathic pulmonary fibrosis: evidence-based guidelines for diagnosis and management. *Am J Respir Crit Care Med* 2011; **183:** 788–824.

4 Raghu G, Weycker D, Edelsberg J, Bradford WZ, Oster G. Incidence and prevalence of idiopathic pulmonary fibrosis. *Am J Respir Crit Care Med* 2006; **174:** 810–16.

5 Hodgson U, Laitinen T, Tukiainen P. Nationwide prevalence of sporadic and familial idiopathic pulmonary fibrosis: evidence of founder effect among multiplex families in Finland. *Thorax* 2002; **57:** 338–42.

6 Gribbin J, Hubbard RB, Le Jeune I, Smith CJ, West J, Tata LJ. Incidence and mortality of idiopathic pulmonary fibrosis and sarcoidosis in the UK. *Thorax* 2006; **61:** 980–85.

7 van Moorsel CH, van Oosterhout MF, Barlo NP, et al. Surfactant protein C mutations are the basis of a significant portion of adult familial pulmonary fibrosis in a Dutch cohort. *Am J Respir Crit Care Med* 2010; **182:** 1419–25.

8 Alakhras M, Decker PA, Nadrous HF, Collazo-Clavell M, Ryu JH. Body mass index and mortality in patients with idiopathic pulmonary fibrosis. *Chest* 2007; **131:** 1448–53.

9 Gribbin J, Hubbard R, Smith C. Role of diabetes mellitus and gastro-oesophageal reflux in the aetiology of idiopathic pulmonary fibrosis. *Respir Med* 2009; **103:** 927–31.

10 Lee JS, Collard HR, Raghu G, et al. Does chronic microaspiration cause idiopathic pulmonary fibrosis? *Am J Med* 2010; **123:** 304–11.

11 Nadrous HF, Pellikka PA, Krowka MJ, et al. Pulmonary hypertension in patients with idiopathic pulmonary fibrosis. *Chest* 2005; **128:** 2393–99.

12 Lancaster LH, Mason WR, Parnell JA, et al. Obstructive sleep apnea is common in idiopathic pulmonary fibrosis. *Chest* 2009; **136:** 772–78.

13 Nathan SD, Basavaraj A, Reichner C, et al. Prevalence and impact of coronary artery disease in idiopathic pulmonary fibrosis. *Respir Med* 2010; **104:** 1035–41.

14 Cottin V, Le Pavec J, Prevot G, et al. Pulmonary hypertension in patients with combined pulmonary fibrosis and emphysema syndrome. *Eur Respir J* 2010; **35:** 105–11.

15 Flaherty KR, King TE Jr, Raghu G, et al. Idiopathic interstitial pneumonia: what is the effect of a multidisciplinary approach to diagnosis? *Am J Respir Crit Care Med* 2004; **170:** 904–10.

16 Song JW, Do KH, Kim MY, Jang SJ, Colby TV, Kim DS. Pathologic and radiologic differences between idiopathic and collagen vascular disease-related usual interstitial pneumonia. *Chest* 2009; **136:** 23–30.

17 Ley B, Collard HR, King TE Jr. Clinical course and prediction of survival in idiopathic pulmonary fibrosis. *Am J Respir Crit Care Med* 2011; **183:** 431–40.

18 van den Blink B, Wijsenbeek MS, Hoogsteden HC. Serum biomarkers in idiopathic pulmonary fibrosis. *Pulm Pharmacol Ther* 2010; **23:** 515–20.

19 Selman M, Carrillo G, Estrada A, et al. Accelerated variant of idiopathic pulmonary fibrosis: clinical behavior and gene expression pattern. *PloS One* 2007; **2:** e482.

20 Boon K, Bailey NW, Yang J, et al. Molecular phenotypes distinguish patients with relatively stable from progressive idiopathic pulmonary fibrosis (IPF). *PLoS One* 2009; **4:** e5134.

21 Collard HR, Moore BB, Flaherty KR, et al. Acute exacerbations of idiopathic pulmonary fibrosis. *Am J Respir Crit Care Med* 2007; **176:** 636–43.

22 Tomioka H, Sakurai T, Hashimoto K, Iwasaki H. Acute exacerbation of idiopathic pulmonary fibrosis: role of Chlamydophila pneumoniae infection. *Respirology* 2007; **12:** 700–06.

23 Silva CIS, Muller NL, Fujimoto K, et al. Acute exacerbation of chronic interstitial pneumonia: high-resolution computed tomography and pathologic findings. *J Thorac Imaging* 2007; **22:** 221–29.

24 King TE Jr, Albera C, Bradford WZ, et al. Effect of interferon gamma-1b on survival in patients with idiopathic pulmonary fibrosis (INSPIRE): a multicentre, randomised, placebo-controlled trial. *Lancet* 2009; **374:** 222–28.

25 Song JW, Hong SB, Lim CM, Koh Y, Kim DS. Acute exacerbation of idiopathic pulmonary fibrosis: incidence, risk factors and outcome. *Eur Respir J* 2011; **37:** 356–63.

26 Wootton, SC, Kim DS, Kondoh Y, et al. Viral Infection in Acute Exacerbation of Idiopathic Pulmonary Fibrosis. *Am J Respir Crit Care Med* 2011; published online Feb 25. DOI:10.1164/rccm.201010-1752OC.

27 Konishi K, Gibson KF, Lindell KO, et al. Gene expression profiles of acute exacerbations of idiopathic pulmonary fibrosis. *Am J Respir Crit Care Med* 2009; **180:** 167–75.

28 Moeller A, Gilpin SE, Ask K, et al. Circulating fibrocytes are an indicator of poor prognosis in idiopathic pulmonary fibrosis. *Am J Respir Crit Care Med* 2009; **179:** 588–94.

29 Mejia M, Carrillo G, Rojas-Serrano J, et al. Idiopathic pulmonary fibrosis and emphysema: decreased survival associated with severe pulmonary arterial hypertension. *Chest* 2009; **136:** 10–15.

30 Silva DR, Gazzana MB, Barreto SS, Knorst MM. Idiopathic pulmonary fibrosis and emphysema in smokers. *J Bras Pneumol* 2008; **34:** 779–86.

31 Lettieri CJ, Nathan SD, Barnett SD, Ahmad S, Shorr AF. prevalence and outcomes of pulmonary arterial hypertension in advanced idiopathic pulmonary fibrosis. *Chest* 2006; **129:** 746–52.

32 Hamada K, Nagai S, Tanaka S, et al. significance of pulmonary arterial pressure and diffusion capacity of the lung as prognosticator in patients with idiopathic pulmonary fibrosis. *Chest* 2007; **131:** 650–56.

33 Fell CD, Martinez FJ. The impact of pulmonary arterial hypertension on idiopathic pulmonary fibrosis. *Chest* 2007; **131:** 641–43.

34 Bouros D, Hatzakis K, Labrakis H, Zeibecoglou K. Association of malignancy with diseases causing interstitial pulmonary changes. *Chest* 2002; **121:** 1278–89.

35 Hironaka M, Fukayama M. Pulmonary fibrosis and lung carcinoma: a comparative study of metaplastic epithelia in honeycombed areas of usual interstitial pneumonia with or without lung carcinoma. *Pathol Int* 1999; **49:** 1060–66.

36 Kawasaki H, Ogura T, Yokose T, Nagai K, Nishiwaki Y, Esumi H. p53 gene alteration in atypical epithelial lesions and carcinoma in patients with idiopathic pulmonary fibrosis. *Human pathology* 2001; **32:** 1043–49.

37 Oshikawa K, Sugiyama Y. Serum anti-p53 autoantibodies from patients with idiopathic pulmonary fibrosis associated with lung cancer. *Respir Med* 2000; **94:** 1085–91.

38 Uematsu K, Yoshimura A, Gemma A, et al. Aberrations in the fragile histidine triad (FHIT) gene in idiopathic pulmonary fibrosis. *Cancer Res* 2001; **61:** 8527–33.

39 Bando M, Takahashi M, Ohno S, et al. Torque teno virus DNA titre elevated in idiopathic pulmonary fibrosis with primary lung cancer. *Respirology* 2008; **13:** 263–69.

40 Wang Y, Kuan PJ, Xing C, et al. Genetic defects in surfactant protein A2 are associated with pulmonary fibrosis and lung cancer. *Am J Hum Genet* 2009; **84:** 52–59.

41 Selman M, King TE Jr, Pardo A. Idiopathic pulmonary fibrosis: prevailing and evolving hypotheses about its pathogenesis and implications for therapy. *Ann Intern Med* 2001; **134:** 136–51.

42 Gilani SR, Vuga LJ, Lindell KO, et al. CD28 down-regulation on circulating CD4 T-cells is associated with poor prognoses of patients with idiopathic pulmonary fibrosis. *PloS One* 2010; **5:** e8959.

43 Williams K, Malarkey D, Cohn L, Patrick D, Dye J, Toews G. Identification of spontaneous feline idiopathic pulmonary fibrosis: morphology and ultrastructural evidence for a type II pneumocyte defect. *Chest* 2004; **125:** 2278–88.

44 Sisson TH, Mendez M, Choi K, et al. Targeted injury of type II alveolar epithelial cells induces pulmonary fibrosis. *Am J Respir Crit Care Med* 2010; **181:** 254–63.

45 Tang YW, Johnson JE, Browning PJ, et al. Herpesvirus DNA is consistently detected in lungs of patients with idiopathic pulmonary fibrosis. *J Clin Microbiol* 2003; **41:** 2633–40.

46 Kelly BG, Lok SS, Hasleton PS, Egan JJ, Stewart JP. A rearranged form of Epstein-Barr virus DNA is associated with idiopathic pulmonary fibrosis. *Am J Respir Crit Care Med* 2002; **166:** 510–13.

47 Lawson WE, Crossno PF, Polosukhin VV, et al. Endoplasmic reticulum stress in alveolar epithelial cells is prominent in IPF: association with altered surfactant protein processing and herpesvirus infection. *Am J Physiol Lung Cell Mol Physiol* 2008; **294:** L1119–26.

48 Korfei M, Ruppert C, Mahavadi P, et al. Epithelial endoplasmic reticulum stress and apoptosis in sporadic idiopathic pulmonary fibrosis. *Am J Respir Crit Care Med* 2008; **178:** 838–46.

49 Grutters JC, du Bois RM. Genetics of fibrosing lung diseases. *Eur Respir J* 2005; **25:** 915–27.

50 Thomas AQ, Lane K, Phillips J 3rd, et al. Heterozygosity for a surfactant protein C gene mutation associated with usual interstitial pneumonitis and cellular nonspecific interstitial pneumonitis in one kindred. *Am J Respir Crit Care Med* 2002; **165:** 1322–28.

51 Seibold MA, Wise AL, Speer MC, et al. A common MUC5B promoter polymorphism and pulmonary fibrosis. *N Engl J Med* 2011; **364:** 1503–12.

52 Zhang Y, Noth I, Garcia JGN, Kaminski N. A variant in the promoter of *MUC5B* and idiopathic pulmonary fibrosis. *N Engl J Med* 2011; **364:** 1576–77.

53 Hodgson U, Pulkkinen V, Dixon M, et al. ELMOD2 is a candidate gene for familial idiopathic pulmonary fibrosis. *Am J Hum Genet* 2006; **79:** 149–54.

54 Pulkkinen V, Bruce S, Rintahaka J, et al. ELMOD2, a candidate gene for idiopathic pulmonary fibrosis, regulates antiviral responses. *FASEB J* 2010; **24:** 1167–77.

55 Selman M, Pardo A, Kaminski N. Idiopathic pulmonary fibrosis: aberrant recapitulation of developmental programs? *PLoS Med* 2008; **5:** e62.

56 Selman M, Pardo A, Barrera L, et al. Gene expression profiles distinguish idiopathic pulmonary fibrosis from hypersensitivity pneumonitis. *Am J Respir Crit Care Med* 2006; **173:** 188–98.

57 Konigshoff M, Balsara N, Pfaff EM, et al. Functional Wnt signaling is increased in idiopathic pulmonary fibrosis. *PloS One* 2008; **3:** e2142.

58 Konigshoff M, Kramer M, Balsara N, et al. WNT1-inducible signaling protein-1 mediates pulmonary fibrosis in mice and is upregulated in humans with idiopathic pulmonary fibrosis. *J Clin Invest* 2009; **119:** 772–87.

59 Vuga LJ, Ben-Yehudah A, Kovkarova-Naumovski E, et al. WNT5A is a regulator of fibroblast proliferation and resistance to apoptosis. *Am J Respir Cell Mol Biol* 2009; **41:** 583–89.

60 Chilosi M, Poletti V, Zamo A, et al. Aberrant Wnt/beta-catenin pathway activation in idiopathic pulmonary fibrosis. *Am J Pathol* 2003; **162:** 1495–502.

61 Keniry M, Parsons R. The role of PTEN signaling perturbations in cancer and in targeted therapy. *Oncogene* 2008; **27:** 5477–85.

62 White ES, Atrasz RG, Hu B, et al. Negative regulation of myofibroblast differentiation by PTEN (phosphatase and tensin homolog deleted on chromosome 10). *Am J Respir Crit Care Med* 2006; **173:** 112–21.

63 Xia H, Diebold D, Nho R, et al. Pathological integrin signaling enhances proliferation of primary lung fibroblasts from patients with idiopathic pulmonary fibrosis. *J Exp Med* 2008; **205:** 1659–72.

64 Stewart GA, Hoyne GF, Ahmad SA, et al. Expression of the developmental Sonic hedgehog (Shh) signalling pathway is up-regulated in chronic lung fibrosis and the Shh receptor patched 1 is present in circulating T lymphocytes. *J Pathol* 2003; **199:** 488–95.

65 Coon DR, Roberts DJ, Loscertales M, Kradin R. Differential epithelial expression of SHH and FOXF1 in usual and nonspecific interstitial pneumonia. *Exp Mol Pathol* 2006; **80:** 119–23.

66 Walsh DW, Godson C, Brazil DP, Martin F. Extracellular BMP-antagonist regulation in development and disease: tied up in knots. *Trends Cell Biol* 2010; **20:** 244–56.

67 Koli K, Myllarniemi M, Vuorinen K, et al. Bone morphogenetic protein-4 inhibitor gremlin is overexpressed in idiopathic pulmonary fibrosis. *Am J Pathol* 2006; **169:** 61–71.

68 Selman M, Pardo A. Role of epithelial cells in idiopathic pulmonary fibrosis: from innocent targets to serial killers. *Proc Am Thorac Soc* 2006; **3:** 364–72.

69 Borensztajn K, Peppelenbosch MP, Spek CA. Factor Xa: at the crossroads between coagulation and signaling in physiology and disease. *Trends Mol Med* 2008; **14:** 429–40.

70 Kim KK, Kugler MC, Wolters PJ, et al. Alveolar epithelial cell mesenchymal transition develops in vivo during pulmonary fibrosis and is regulated by the extracellular matrix. *Proc Natl Acad Sci USA* 2006; **103:** 13180–85.

71 Scotton CJ, Krupiczojc MA, Konigshoff M, et al. Increased local expression of coagulation factor X contributes to the fibrotic response in human and murine lung injury. *J Clin Invest* 2009; **119:** 2550–63.

72 Bogatkevich GS, Tourkina E, Silver RM, Ludwicka-Bradley A. Thrombin differentiates normal lung fibroblasts to a myofibroblast phenotype via the proteolytically activated receptor-1 and a protein kinase C-dependent pathway. *J Biol Chem* 2001; **276:** 45184–92.

73 Andersson-Sjoland A, de Alba CG, Nihlberg K, et al. Fibrocytes are a potential source of lung fibroblasts in idiopathic pulmonary fibrosis. *Int J Biochem Cell Biol* 2008; **40:** 2129–40.

74 Strieter RM, Keeley EC, Hughes MA, Burdick MD, Mehrad B. The role of circulating mesenchymal progenitor cells (fibrocytes) in the pathogenesis of pulmonary fibrosis. *J Leukoc Biol* 2009; **86:** 1111–18.

75 Thiery JP, Acloque H, Huang RY, Nieto MA. Epithelial-mesenchymal transitions in development and disease. *Cell* 2009; **139:** 871–90.

76 Willis BC, Liebler JM, Luby-Phelps K, et al. Induction of epithelial-mesenchymal transition in alveolar epithelial cells by transforming growth factor-beta1: potential role in idiopathic pulmonary fibrosis. *Am J Pathol* 2005; **166:** 1321–32.

77 Larsson O, Diebold D, Fan D, et al. Fibrotic myofibroblasts manifest genome-wide derangements of translational control. *PloS One* 2008; **3:** e3220.

78 Marmai C, Sutherland RE, Kim KK, et al. Alveolar epithelial cells express mesenchymal proteins in patients with idiopathic pulmonary fibrosis. *Am J Physiol Lung Cell Mol Physiol* 2011; published online April 15. DOI:10.1152/ajplung.00212.2010.

79 Willis BC, Borok Z. TGF-beta-induced EMT: mechanisms and implications for fibrotic lung disease. *Am J Physiol Lung Cell Mol Physiol* 2007; **293:** L525–34.

80 Jayachandran A, Konigshoff M, Yu H, et al. SNAI transcription factors mediate epithelial-mesenchymal transition in lung fibrosis. *Thorax* 2009; **64:** 1053–61.

81 Pozharskaya V, Torres-Gonzalez E, Rojas M, et al. Twist: a regulator of epithelial-mesenchymal transition in lung fibrosis. *PloS One* 2009; **4:** e7559.

82 Tanjore H, Xu XC, Polosukhin VV, et al. Contribution of epithelial-derived fibroblasts to bleomycin-induced lung fibrosis. *Am J Respir Crit Care Med* 2009; **180:** 657–65.

83 Hinz B, Phan SH, Thannickal VJ, Galli A, Bochaton-Piallat ML, Gabbiani G. The myofibroblast: one function, multiple origins. *Am J Pathol* 2007; **170:** 1807–16.

84 Wang R, Ramos C, Joshi I, et al. Human lung myofibroblast-derived inducers of alveolar epithelial apoptosis identified as angiotensin peptides. *Am J Physiol* 1999; **277:** L1158–64.

85 Waghray M, Cui Z, Horowitz JC, et al. Hydrogen peroxide is a diffusible paracrine signal for the induction of epithelial cell death by activated myofibroblasts. *Faseb J* 2005; **19:** 854–56.

86 Kulasekaran P, Scavone CA, Rogers DS, Arenberg DA, Thannickal VJ, Horowitz JC. Endothelin-1 and transforming growth factor-beta1 independently induce fibroblast resistance to apoptosis via AKT activation. *Am J Respir Cell Mol Biol* 2009; **41:** 484–93.

87 Thannickal VJ, Horowitz JC. Evolving concepts of apoptosis in idiopathic pulmonary fibrosis. *Proc Am Thorac Soc* 2006; **3:** 350–56.

88 Maher TM, Evans IC, Bottoms SE, et al. Diminished prostaglandin E2 contributes to the apoptosis paradox in idiopathic pulmonary fibrosis. *Am J Respir Crit Care Med* 2010; **182:** 73–82.

89 Wang XM, Zhang Y, Kim HP, et al. Caveolin-1: a critical regulator of lung fibrosis in idiopathic pulmonary fibrosis. *J Exp Med* 2006; **203:** 2895–906.

90 Fehrenbach H, Kasper M, Tschernig T, Shearman MS, Schuh D, Muller M. Receptor for advanced glycation endproducts (RAGE) exhibits highly differential cellular and subcellular localisation in rat and human lung. *Cell Molec Biol* 1998; **44:** 1147–57.

91 Demling N, Ehrhardt C, Kasper M, Laue M, Knels L, Rieber EP. Promotion of cell adherence and spreading: a novel function of RAGE, the highly selective differentiation marker of human alveolar epithelial type I cells. *Cell Tissue Res* 2006; **323:** 475–88.

92 Englert JM, Hanford LE, Kaminski N, et al. A role for the receptor for advanced glycation end products in idiopathic pulmonary fibrosis. *Am J Pathol* 2008; **172:** 583–91.

93 Queisser MA, Kouri FM, Konigshoff M, et al. Loss of RAGE in pulmonary fibrosis: molecular relations to functional changes in pulmonary cell types. *Am J Respir Cell Mol Biol* 2008; **39:** 337–45.

94 Zuo F, Kaminski N, Eugui E, et al. Gene expression analysis reveals matrilysin as a key regulator of pulmonary fibrosis in mice and humans. *Proc Natl Acad Sci USA* 2002; **99:** 6292–97.

95 Selman M, Ruiz V Cabrera S, et al. TIMP-1, -2, -3, and -4 in idiopathic pulmonary fibrosis. A prevailing nondegradative lung microenvironment? *Am J Physiol Lung Cell Mol Physiol* 2000; **279:** L562–74.

96 Garcia-Alvarez J, Ramirez R, Sampieri CL, et al. Membrane type-matrix metalloproteinases in idiopathic pulmonary fibrosis. *Sarcoidosis Vasc Diffuse Lung Dis* 2006; **23:** 13–21.

97 McKeown S, Richter AG, O'Kane C, McAuley DF, Thickett DR. MMP expression and abnormal lung permeability are important determinants of outcome in IPF. *Eur Respir J* 2009; **33:** 77–84.

98 Pardo A, Gibson K, Cisneros J, et al. Up-regulation and profibrotic role of osteopontin in human idiopathic pulmonary fibrosis. *PLoS Med* 2005; **2:** e251.

99 Chen P, Parks WC. Role of matrix metalloproteinases in epithelial migration. *J Cell Biochem* 2009; **108:** 1233–43.

100 Checa M, Ruiz V, Montano M, Velazquez-Cruz R, Selman M, Pardo A. MMP-1 polymorphisms and the risk of idiopathic pulmonary fibrosis. *Hum Genet* 2008; **124:** 465–72.

101 Strieter RM, Gomperts BN, Keane MP. The role of CXC chemokines in pulmonary fibrosis. *J Clin Invest* 2007; **117:** 549–56.

102 Ebina M, Shimizukawa M, Shibata N, et al. Heterogeneous increase in CD34-positive alveolar capillaries in idiopathic pulmonary fibrosis. *Am J Respir Crit Care Med* 2004; **169:** 1203–08.

103 Cosgrove GP, Brown KK, Schiemann WP, et al. Pigment epithelium-derived factor in idiopathic pulmonary fibrosis: a role in aberrant angiogenesis. *Am J Respir Crit Care Med* 2004; **170:** 242–51.

104 Copley SJ, Wells AU, Hawtin KE, et al. Lung morphology in the elderly: comparative CT study of subjects over 75 years old versus those under 55 years old. *Radiology* 2009; **251:** 566–73.

105 Armanios M. Syndromes of telomere shortening. *Ann Rev Genomics Hum Genet* 2009; **10:** 45–61.

106 Armanios MY, Chen JJ, Cogan JD, et al. Telomerase mutations in families with idiopathic pulmonary fibrosis. *N Engl J Med* 2007; **356:** 1317–26.

107 Tsakiri KD, Cronkhite JT, Kuan PJ, et al. Adult-onset pulmonary fibrosis caused by mutations in telomerase. *Proc Natl Acad Sci USA* 2007; **104:** 7552–57.

108 Alder JK, Chen JJ, Lancaster L, et al. Short telomeres are a risk factor for idiopathic pulmonary fibrosis. *Proc Natl Acad Sci USA* 2008; **105:** 13051–56.

109 Savale L, Chaouat A, Bastuji-Garin S, et al. Shortened telomeres in circulating leukocytes of patients with chronic obstructive pulmonary disease. *Am J Respir Crit Care Med* 2009; **179:** 566–71.

110 Lee J, Reddy R, Barsky L, et al. Lung alveolar integrity is compromised by telomere shortening in telomerase-null mice. *Am J Physiol Lung Cell Mol Physiol* 2009; **296:** L57–70.

111 Tsuji T, Aoshiba K, Nagai A. Alveolar cell senescence in patients with pulmonary emphysema. *Am J Respir Crit Care Med* 2006; **174:** 886–93.

112 Segura-Valdez L, Pardo A, Gaxiola M, Uhal BD, Becerril C, Selman M. Upregulation of gelatinases A and B, collagenases 1 and 2, and increased parenchymal cell death in COPD. *Chest* 2000; **117:** 684–94.

113 Calabrese F, Giacometti C, Beghe B, et al. Marked alveolar apoptosis/proliferation imbalance in end-stage emphysema. *Respir Res* 2005; **6:** 14.

114 Imai K, Mercer BA, Schulman LL, Sonett JR, D'Armiento JM. Correlation of lung surface area to apoptosis and proliferation in human emphysema. *Eur Respir J* 2005; **25:** 250–58.

115 Selman M, Rojas M, Mora AL, Pardo A. Aging and interstitial lung diseases: unraveling an old forgotten player in the pathogenesis of lung fibrosis. *Semin Respir Crit Care Med* 2010; **31:** 607–17.

116 Kinnula VL, Fattman CL, Tan RJ, Oury TD. Oxidative stress in pulmonary fibrosis: a possible role for redox modulatory therapy. *Am J Respir Crit Care Med* 2005; **172:** 417–22.

117 Walters DM, Cho HY, Kleeberger SR. Oxidative stress and antioxidants in the pathogenesis of pulmonary fibrosis: a potential role for Nrf2. *Antioxid Redox Signal* 2008; **10:** 321–32.

118 Christensen BC, Houseman EA, Marsit CJ, et al. Aging and environmental exposures alter tissue-specific DNA methylation dependent upon CpG island context. *PLoS Genet* 2009; **5:** e1000602.

119 Sharma S, Kelly TK, Jones PA. Epigenetics in cancer. *Carcinogenesis* 2010; **31:** 27–36.

120 Sanders YY, Pardo A, Selman M, et al. Thy-1 promoter hypermethylation: a novel epigenetic pathogenic mechanism in pulmonary fibrosis. *Am J Respir Cell Mol Biol* 2008; **39:** 610–18.

121 Wilborn J, Crofford LJ, Burdick MD, Kunkel SL, Strieter RM, Peters-Golden M. Cultured lung fibroblasts isolated from patients with idiopathic pulmonary fibrosis have a diminished capacity to synthesize prostaglandin E2 and to express cyclooxygenase-2. *J Clin Invest* 1995; **95:** 1861–68.

122 Coward WR, Watts K, Feghali-Bostwick CA, Knox A, Pang L. Defective histone acetylation is responsible for the diminished expression of cyclooxygenase 2 in idiopathic pulmonary fibrosis. *Mol Cell Biol* 2009; **29:** 4325–39.

123 Lanceta J, Prough RA, Liang R, Wang E. MicroRNA group disorganization in aging. *Exp Gerontol* 2010; **45:** 269–78.

124 Pandit KV, Corcoran D, Yousef H, et al. Inhibition and role of let-7d in idiopathic pulmonary fibrosis. *Am J Respir Crit Care Med* 2010; **182:** 220–29.

125 Liu G, Friggeri A, Yang Y, et al. miR-21 mediates fibrogenic activation of pulmonary fibroblasts and lung fibrosis. *J Exp Med* 2010; **207:** 1589–97.

126 Cushing L, Kuang PP, Qian J, et al. MIR-29 is a major regulator of genes associated with pulmonary fibrosis. *Am J Respir Cell Mol Biol* 2010; published online Oct 22. DOI:10.1165/rcmb.2010-0323OC.

127 Raghu G, Brown KK, Costabel U, et al. Treatment of idiopathic pulmonary fibrosis with etanercept: an exploratory, placebo-controlled trial. *Am J Respir Crit Care Med* 2008; **178:** 948–55.

128 Raghu G, Brown KK, Bradford WZ, et al. A placebo-controlled trial of interferon gamma-1b in patients with idiopathic pulmonary fibrosis. *N Engl J Med* 2004; **350:** 125–33.

129 King Jr TE, Brown KK, Raghu G, et al. BUILD-3: a randomized, controlled trial of bosentan in idiopathic pulmonary fibrosis. *Am J Respir Crit Care Med* 2011; published online April 7. DOI:10.1164/rccm.201011-1874OC.

130 Daniels CE, Lasky JA, Limper AH, Mieras K, Gabor E, Schroeder DR. Imatinib treatment for idiopathic pulmonary fibrosis: randomized placebo-controlled trial results. *Am J Respir Crit Care Med* 2010; **181:** 604–10.

131 Demedts M, Behr J, Buhl R, et al. High-dose acetylcysteine in idiopathic pulmonary fibrosis. *N Engl J Med* 2005; **353:** 2229–42.

132 Taniguchi H, Ebina M, Kondoh Y, et al. Pirfenidone in idiopathic pulmonary fibrosis. *Eur Respir J* 2010; **35:** 821–29.

133 Noble PW, Albera C, Bradford WZ, et al. Pirfenidone in patients with idiopathic pulmonary fibrosis (CAPACITY): two randomised trials. *Lancet* 2011; **377:** 1760–69.

134 Kubo H, Nakayama K, Yanai M, et al. Anticoagulant therapy for idiopathic pulmonary fibrosis. *Chest* 2005; **128:** 1475–82.

135 Thabut G, Christie JD, Ravaud P, et al. survival after bilateral versus single-lung transplantation for idiopathic pulmonary fibrosis. *Ann Intern Med* 2009; **151:** 767–74.

136 Weiss DJ, Kolls JK, Ortiz LA, Panoskaltsis-Mortari A, Prockop DJ. Stem cells and cell therapies in lung biology and lung diseases. *Proc Am Thorac Soc* 2008; **5:** 637–67.

137 Crosby LM, Waters CM. Epithelial repair mechanisms in the lung. *Am J Physiol Lung Cell Mol Physiol* 2010; **298:** L715–31.

138 Ortiz LA, Gambelli F, McBride C, et al. Mesenchymal stem cell engraftment in lung is enhanced in response to bleomycin exposure and ameliorates its fibrotic effects. *Proc Natl Acad Sci USA* 2003; **100:** 8407–11.

139 Germano D, Blyszczuk P, Valaperti A, et al. Prominin-1/CD133+ lung epithelial progenitors protect from bleomycin-induced pulmonary fibrosis. *Am J Respir Crit Care Med* 2009; **179:** 939–49.

140 Wang D, Morales JE, Calame DG, Alcorn JL, Wetsel RA. Transplantation of human embryonic stem cell-derived alveolar epithelial type II cells abrogates acute lung injury in mice. *Mol Ther* 2010; **18:** 625–34.

141 Petersen TH, Calle EA, Zhao L, et al. Tissue-engineered lungs for in vivo implantation. *Science* 2010; **329:** 538–41.

142 Ghofrani HA, Wiedemann R, Rose F, et al. Sildenafil for treatment of lung fibrosis and pulmonary hypertension: a randomised controlled trial. *Lancet* 2002; **360:** 895–900.

143 Zisman DA, Schwarz M, Anstrom KJ, Collard HR, Flaherty KR, Hunninghake GW. A controlled trial of sildenafil in advanced idiopathic pulmonary fibrosis. *N Engl J Med* 2010; **363:** 620–28.